

# American Journal of Sports Medicine

<http://ajs.sagepub.com>

---

## Comparison of Surgically Repaired Achilles Tendon Tears Using Platelet-Rich Fibrin Matrices

Mikel Sánchez, Eduardo Anitua, Juan Azofra, Isabel Andía, Sabino Padilla and Iñigo Mujika

*Am. J. Sports Med.* 2007; 35; 245 originally published online Nov 12, 2006;

DOI: 10.1177/0363546506294078

The online version of this article can be found at:  
<http://ajs.sagepub.com/cgi/content/abstract/35/2/245>

---

Published by:



<http://www.sagepublications.com>

On behalf of:



[American Orthopaedic Society for Sports Medicine](http://www.aospor.org)

**Additional services and information for *American Journal of Sports Medicine* can be found at:**

**Email Alerts:** <http://ajs.sagepub.com/cgi/alerts>

**Subscriptions:** <http://ajs.sagepub.com/subscriptions>

**Reprints:** <http://www.sagepub.com/journalsReprints.nav>

**Permissions:** <http://www.sagepub.com/journalsPermissions.nav>

**Citations** (this article cites 27 articles hosted on the  
SAGE Journals Online and HighWire Press platforms):  
<http://ajs.sagepub.com/cgi/content/abstract/35/2/245#BIBL>

# Comparison of Surgically Repaired Achilles Tendon Tears Using Platelet-Rich Fibrin Matrices

Mikel Sánchez,\* MD, Eduardo Anitua,<sup>†</sup> MD, DDS, Juan Azofra,\* MD, Isabel Andía,<sup>†</sup> PhD, Sabino Padilla,<sup>‡</sup> MD, PhD, and Iñigo Mujika,<sup>‡§</sup> PhD

From the \*Arthroscopic Surgery Unit, USP–La Esperanza Clinic, Vitoria-Gasteiz, Basque Country, Spain, the <sup>†</sup>BTI Biotechnology Institute, Vitoria-Gasteiz, Basque Country, Spain, and the <sup>‡</sup>Department of Research and Development, Medical Services, Athletic Club Bilbao, Basque Country, Spain

---

**Background:** Platelet-rich fibrin matrices release a natural mixture of growth factors that play central roles in the complex processes of tendon healing.

**Hypothesis:** Application of autologous platelet-rich matrices during Achilles tendon surgery may promote healing and functional recovery.

**Study Design:** Case-control study and descriptive laboratory study; Level of evidence, 3.

**Methods:** Twelve athletes underwent open suture repair after complete Achilles tendon tear. Open suture repair in conjunction with a preparation rich in growth factors (PRGF) was performed in 6 athletes and retrospectively compared with a matched group that followed conventional surgical procedure. The outcomes were evaluated on the basis of range of motion, functional recovery, and complications. Achilles tendons were examined by ultrasound at  $50 \pm 11$  months in retrospective controls and  $32 \pm 10$  months in the PRGF group. In the laboratory portion of the study, PRGF treatment was characterized by the number of platelets and concentration of insulin (IGF-I), transformed (TGF- $\beta$ 1), platelet-derived (PDGF-AB), vascular endothelial (VEGF), hepatocyte (HGF), and epidermal (EGF) growth factors in patients affected by musculoskeletal traumatic injuries.

**Results:** Athletes receiving PRGF recovered their range of motion earlier ( $7 \pm 2$  weeks vs  $11 \pm 3$  weeks,  $P = .025$ ), showed no wound complication, and took less time to take up gentle running ( $11 \pm 1$  weeks vs  $18 \pm 3$  weeks,  $P = .042$ ) and to resume training activities ( $14 \pm 0.8$  weeks vs  $21 \pm 3$  weeks,  $P = .004$ ). The cross-sectional area of the PRGF-treated tendons increased less ( $t = 3.44$ ,  $P = .009$ ). TGF- $\beta$ 1 ( $74.99 \pm 32.84$  ng/mL), PDGF-AB ( $35.62 \pm 14.57$  ng/mL), VEGF ( $383.9 \pm 374.9$  pg/mL), EGF ( $481.5 \pm 187.5$  pg/mL), and HGF ( $593.87 \pm 155.76$  pg/mL) significantly correlated with the number of platelets ( $677 \pm 217$  platelets/ $\mu$ L,  $P < .05$ ).

**Conclusion:** The operative management of tendons combined with the application of autologous PRGF may present new possibilities for enhanced healing and functional recovery. This needs to be evaluated in a randomized clinical trial.

**Keywords:** sports; platelets; growth factors; surgical repair; Achilles tendon

---

Epidemiologic reports indicate that rupture of the Achilles tendon has become a common problem with an increasing

incidence in modern society, especially among athletes.<sup>16,17</sup> Because of its limited blood supply and slow cell turnover, the ruptured Achilles tendon heals slowly, often requiring surgical treatment and several months for full recovery of functional capacities. Tendon healing is a complex process that involves several stages, including angiogenesis, cell proliferation, and the deposition of extracellular matrix. These stages are followed by remodeling and maturation, during which the healing tendon should ultimately regain its mechanical strength.

Healing is promoted in particular by certain growth factors acting directly on target cells present in the injured site. In animal models, upregulated temporal expression of some growth factors and their receptors has been reported

---

<sup>§</sup>Address correspondence to Iñigo Mujika, PhD, Athletic Club Bilbao, Sports Facilities, Garaioltza 147, Lezama, Bizkaia, Spain (e-mail: inigo.mujika@euskalnet.net).

One or more of the authors has declared a potential conflict of interest: Eduardo Anitua is the scientific director and Isabel Andía is the research director of a company that commercializes a system for obtaining a platelet-rich preparation.

during the healing process of tendinous tissue.<sup>10,14</sup> Furthermore, the healing tendon is also responsive to local application of growth factors.<sup>1,13,20,24,27,34</sup> An autologous platelet-rich fibrin (prepared from platelet-rich plasma) secretes a complex mixture of biological mediators essential to natural repair, including transforming growth factor- $\beta$ 1 (TGF- $\beta$ 1), platelet-derived growth factor (PDGF), vascular endothelial growth factor (VEGF), epithelial growth factor (EGF), hepatocyte growth factor (HGF), and insulin-like growth factor (IGF-I). Because most of these growth factors have been identified as playing key roles in tendon healing,<sup>15,24</sup> the use of autologous platelet-rich plasma has been proposed as a strategy for enhancing the cellular response to injury within the tendon and, ultimately, the quality of repair.

An interesting new feature of the physiologic function of platelets is their role as vehicles for the local delivery of growth factors in wound healing.<sup>4</sup> At sites of vascular injury, platelets adhere and aggregate and also generate thrombin, which triggers the production of a fibrin matrix from fibrinogen.

To derive benefit from this natural mechanism, we have developed a procedure in which  $\text{Ca}^{2+}$  is added to plasma enriched in platelets, triggering the formation of a fibrin matrix containing embedded platelets. The resulting preparation rich in growth factors (PRGF) allows the slow release of biologically active proteins that initiate and modulate wound healing in both soft and hard tissues.<sup>4,6</sup>

Previous studies by our group have shown that tendon cells *in vitro* respond to the secreted pool of growth factors by proliferating, a basic response fundamental for repair. Moreover, and also crucial for tissue healing, this treatment elicited an angiogenic response based on the synthesis of VEGF and HGF by tendon cells.<sup>5</sup> This could be especially relevant to the vascular status of tendons, assuming that the low healing capability of tendons is associated with a reduced blood supply when compared with other tissues. From a kinetic point of view, fibrin matrix exerts a control of growth factor release mimicking natural expression patterns; this fact promoted a further examination of tendon cells cultured on autologous fibrin matrices and the effects of their administration *in vivo*. Results demonstrated that PRGF is a safe strategy to accelerate tendon cell proliferation, stimulate the synthesis of type I collagen, and promote neovascularization both *in vivo* and *in vitro*.<sup>8</sup> Moreover, other studies have reported the potential impact of platelet-rich fibrin on impaired wound healing,<sup>12</sup> which is considered the major potential complication associated with operative treatment of the Achilles tendon.<sup>11,18</sup>

All these arguments provided the fundamentals for testing the defined PRGF in conjunction with the surgical treatment of a ruptured Achilles tendon in a preliminary observational study in athletes, for whom accelerated functional recovery is essential. Before February 2002, Achilles tendon surgery was performed using a surgical procedure previously described.<sup>31</sup> After February 2002, a method for the application of PRGF during surgery was introduced. Thus, we were able to study and compare 2 groups of patients: those who underwent the conventional surgical procedure and those who underwent the same procedure combined with autologous PRGF therapy.

## PATIENTS AND METHODS

### Patients

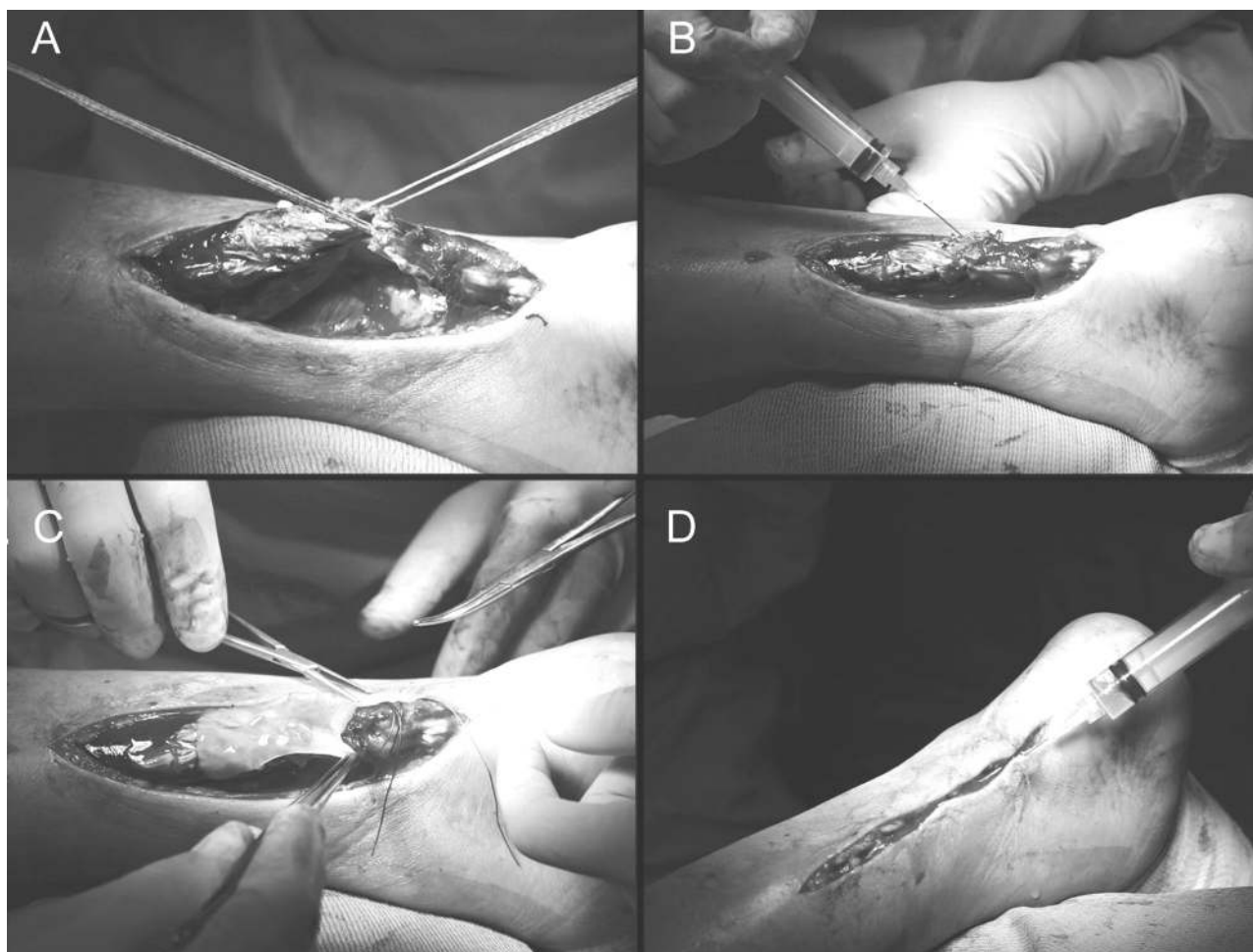
Twelve athletes with spontaneous complete rupture of the Achilles tendon were treated operatively at the Arthroscopic Surgery Unit, USP-La Esperanza Clinic, Vitoria-Gasteiz, Spain, between 1997 and 2004. Approval by the local ethics committee for the prospective use of PRGF and written informed consent were obtained. Exclusion criteria were previous tendon injury, history of diabetes mellitus, platelet abnormality, hematologic abnormality, serum hemoglobin concentration  $<11$  g/dL or hematocrit  $<34\%$ , use of systemic cortisone, and current use of anticoagulants. A 2-step application method of platelet-rich therapy in conjunction with reconstructive surgery was performed in 6 athletes treated from 2002 to 2004 (Figure 1). Six of 11 athletes treated from 1997 to 2001, selected by the same mechanism of injury, matched by age, gender, and physical activities, and who had the identical surgery procedure but without the application of platelet-rich therapy, were identified retrospectively.

Two experienced orthopaedic surgeons of our group (M.S. and J.A.) performed all surgeries. All patients were male; descriptors of both groups are summarized in Table 1. Clinical evaluation and a positive Thompson sign, followed by complementary ultrasound study (Logic 400 MD, GE Medical Systems, Milwaukee, Wis) or magnetic resonance imaging (high-resolution 1.5-T Magnetom Vision unit, Siemens, Erlangen, Germany) were used to diagnose and confirm the complete Achilles tendon rupture in all patients. All cases were operated on no later than 2 weeks from the time of rupture.

### Preparation and Characterization of PRGF

We studied quantitative aspects of PRGF in a group of 21 volunteers affected by ligament, tendon, or muscle traumatic injuries, including the 6 athletes operated on with PRGF. The mean age of donors was  $30.7 \pm 7.1$  years. Blood was collected in tubes with 5 mL trisodium citrate, and then centrifuged at 460g for 8 minutes (PRGF System II, BTI, Vitoria-Gasteiz, Spain). The 1-mL fractions immediately above the erythrocyte pellet were collected from each tube and transferred to sterile tubes, and the platelet count was determined. Care was taken to avoid collecting the buffy coat.

For the *in vitro* determinations, a platelet-rich fibrin matrix was formed by adding calcium chloride at a final concentration of 22.8 mM; clots were allowed to retract for 1 hour at 37°C. The released supernatants were assayed to provide relevant information about the concentration of potentially therapeutic growth factors in platelet-rich plasma preparations such as PDGF-AB, TGF- $\beta$ 1, VEGF, EGF, and plasmatic factors such as IGF-I and HGF. All these factors were assessed utilizing commercially available enzyme-linked immunosorbent assay kits (Quantikine colorimetric ELISA kits, R&D, Minneapolis, Minn), used according to the manufacturer's instructions. All measurements were performed in triplicate, and no unexpected scattering of the data ( $<10\%$ ) was observed.



**Figure 1.** The surgical procedure applying preparation rich in growth factors (PRGF). A, the ruptured ends of the Achilles tendon are approximated and sutured. B, injection of calcified unclotted plasma within the fascicles; the fibrin matrix develops in situ. C, the affected area is covered with an autologous platelet-rich fibrin matrix before closure of the overlying skin. D, subcutaneous infiltration of calcified unclotted PRGF before suturing.

For the surgical procedure, 40 mL of blood was drawn by puncture from an antecubital vein 20 to 30 minutes before surgery and before the administration of anesthesia. Platelet-rich plasma was separated as explained above. Four milliliters were supplemented with calcium chloride at a final concentration of 22.8 mM and left to rest for 30 minutes in a glass container, allowing the fibrin scaffold to develop before grafting. In addition, 4 mL of injectable PRGF, in which calcium chloride was added just before application, was prepared.

**Surgical Procedure**

The same surgical technique was used in both groups. Briefly, after debridement of the tendon edges, a polydioxanone (PDS) tape 5 mm large and 60 cm in length (Ethicon Inc, Johnson & Johnson, Brussels, Belgium) is placed with a V-40 half-circle needle using a Kessler technique in the proximal stump. A second suture is placed in the distal stump. The knee is then flexed, and the foot is plantar flexed; the ends of the suture can be tied without tension.<sup>31</sup>

**TABLE 1**  
 Characteristics of Patients With Acute Rupture of Achilles Tendon<sup>a</sup>

Characteristic	PRGF (n = 6)	Control (n = 6)
Age at time of surgery, y	36.2 (6.2)	32.1 (6.0)
Sporting activity		
Soccer	4	1
Basketball	2	2
Volleyball	0	1
Racquet sports	0	2
Elite athletes/recreational	2/4	1/5
Time between rupture and operation, d	5.8 (1.3)	4.0 (2.8)
Injured during sporting activity	5	5
Injured during walking	1	1
Affected side, right/left	4/2	2/4

<sup>a</sup>PRGF, preparation rich in growth factors. Applicable values are mean (SD); no significant differences were found.

The repair is then augmented using a 0-coated Vicril (CP Medical, Johnson & Johnson, Belgium) vertical locking circumferential suture. In the platelet-rich treated group, approximately 4 mL of the activated plasma was injected among the tendon fibers after the tendon was sutured. After closing the paratenon and before closing the overlying skin, the affected area was covered with the fibrin scaffold prepared as described above (Figure 1). Patients received a single preoperative dose of 2 g intravenous cefonicid (Rottapharm, Valencia, Spain); a subcutaneous dose of 2500 UI bempiparine (Hibor, Laboratorios Rovi, Madrid, Spain) was administered daily for 3 weeks postoperatively, and 500 mg diclofenac was administered twice daily for a period up to 10 days or longer postoperatively as needed based on the pain response.

### Postoperative Treatment

A below-knee plaster cast with neutral position of the ankle was used for 2 to 3 weeks; patients were allowed to walk with elbow crutches for this period. At 2 to 3 weeks, the cast was removed, and the patients commenced an active rehabilitation protocol instructed and supervised by a physical therapist blinded to the surgical treatment. A reduction in heel size (1.5 cm), followed by a gradual increase in active and passive dorsiflexion, was begun. Unloaded stationary bicycling and swimming were included later in this phase. Patients were authorized to begin running daily for about 10 minutes based on tactile exploration, recovery of movement and calf strength (based on the 1-footed tiptoe test, in which subjects are required to stand on tiptoes of the injured side for 5 seconds, 10 times), and examination of ultrasonographic scans; intensity and duration were increased gradually as the patients felt able.

### Outcome Evaluation

Patients were examined by the operating surgeons; in general, time frames of follow-up were scheduled every other week during the first month, every 4 to 6 weeks up to 6 months, and then after 9 and 12 months. Functional outcome evaluation was based on the following 3 indicators: time necessary to reach full range of motion, time needed to take up gentle running, and time to resume training activities. The range of motion of the ankle was measured using a goniometer (Biomet Inc, Warsaw, Ind) and compared with the contralateral ankle. The date on which surgeons authorized gentle running according to the criteria above was used as an outcome indicator. Complications such as infections, wound healing defects, subcutaneous tendon adhesions, symptoms of sural nerve injury, and calcifications were evaluated in both groups. Final decisions regarding suitability to return to practice and competition remained solely with the sports medicine staff of each club. Data derived from closed questions to the patients based on a simplified construct of Cincinnati function scales<sup>30</sup> were used to define the elapsed time to get back to sporting activities, normal training, and competition.

### Long-term Ultrasound Examination

All patients underwent standardized ultrasound evaluation by 2 experienced musculoskeletal radiologists blinded to the surgical treatment (Logic 400 MD, GE Medical Systems, with 7.5-12.0 MHz linear array transducer). The interval between surgery and this examination was different between groups (control,  $50 \pm 11$  months; PRGF,  $32 \pm 10$  months); however, both time intervals are long enough to ensure complete remodeling of the scar. Patients were examined in the prone position with the affected foot hanging over the end of the examination table. For each subject, ultrasound scans were performed at both Achilles tendons, 4 to 5 cm proximal to the insertion with the ankle in neutral position ( $90^\circ$  of flexion). The Achilles tendon was scanned transversely with the transducer perpendicular to the Achilles tendon. The transducer was angled cranially and caudally until the scan plane showed an Achilles tendon with maximum echogenicity. The cross-sectional area of the Achilles tendon was measured by trace ellipse method so that the ellipse just surrounded the echogenic boundary of the Achilles tendon.<sup>33</sup> The intraclass correlation coefficient (ICC) of the cross-sectional area was 0.891; the upper 95% confidence interval (CI) was 0.915; the lower 95% CI was 0.841, indicating a reproducibility of 89%. The cross-sectional area of the contralateral asymptomatic tendon was used as a reference to calculate the percentage of the increase.

### Statistical Analysis

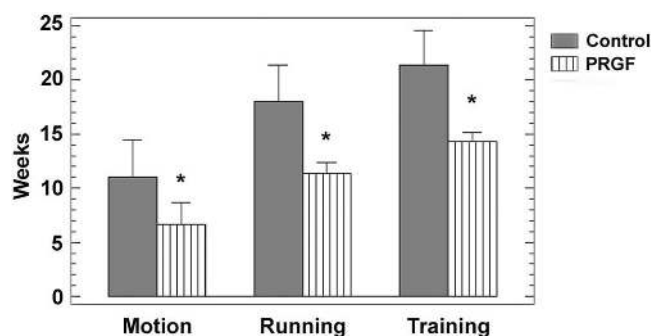
All results are expressed as mean  $\pm$  SD. Significant differences among groups were evaluated using the Mann-Whitney *U* test. The mean cross-sectional area was compared using the Student *t* test. Scatter plots and Pearson correlations were used to examine the relationship between platelet counts and growth factor concentrations. A difference of  $P < .05$  was considered to be statistically significant (Statgraphics Plus, Manugistic, Rockville, Md).

## RESULTS

### Clinical Outcome

All ruptures were localized in the main body of the tendon, at 4 to 5 cm proximal to the calcaneus insertion. Hospital stay was 48 hours for all patients. No patient had major complications such as rerupture or deep infection. All wound complications appeared in the control group. Two patients presented keloid scars, but they did not require further treatment. Another patient suffered a superficial skin and subcutaneous infection 6 weeks after surgery and required surgical debridement that was followed by primary closure. We did not find any calcification or altered sensation in any patient.

As shown in Table 1, sports activities were different between the 2 groups, and patients in the PRGF group had a higher demand of running and jumping. Figure 2 shows the differences in the functional recovery of both groups.



**Figure 2.** Differences in the functional recovery of 6 athletes treated with preparation rich in growth factors (PRGF) during surgical reconstruction and a matched group that followed conventional surgical procedure. Indices of functional outcome: time necessary to reach total motion, take up gentle running, and resume training activities (mean  $\pm$  SD). \* $P < .05$ .

All 3 indices of functional outcome (attainment of full range of ankle motion, time needed to be able to run gently, and time to resume normal training activities) were significantly faster in the PRGF-treated group. At the individual level, 2 professional athletes (soccer and basketball) treated with PRGF returned to competition at a level similar to preinjury within 14 weeks after surgery. Two of the amateur athletes in the PRGF group (soccer and basketball) attained preinjury level by 6 months, whereas the 2 remaining athletes (soccer) retired from competitive sports for reasons other than the injury; however, their level of activity was high (level 1 to 2, Cincinnati Scale). Before injury, the Cincinnati Sports Activity Scale<sup>30</sup> was similar for control ( $90 \pm 12$  points) and PRGF athletes ( $88 \pm 11$  points). PRGF patients attained the same sports activity scores at 14 weeks (range, 2 weeks), while control athletes scored  $82 \pm 11$  points at 22 weeks (range, 8 weeks). In the control group, 1 amateur athlete (basketball) returned to competitive participation and 5 athletes retired; this was a common feature in Achilles tendon repairs during this period. Despite retiring from competitive participation, all subjects reported they were in good fitness and continued performing in sport activities at a lower level and did not indicate any functional problem.

#### Long-term Ultrasonographic Evaluation of Operated Tendon

In both groups, the cross-sectional area of the operated tendon was significantly greater than the contralateral tendons. The mean increase in cross-sectional area of the repaired Achilles tendon 4 to 5 cm from the insertion in the calcaneus was  $298\% \pm 90\%$  and  $499\% \pm 91\%$  for the PRGF and the control group, respectively ( $t = 3.44$ ,  $P = .009$ ).

#### PRGF Characterization: Platelet Counts and Levels of Growth Factors

Initially, a full characterization of the main growth factors released from activated PRGF was performed. These data

are particularly important because the growth factors are directly implicated in the healing process. For this aim, growth factor concentration was determined in the PRGF obtained from a total of 21 donors. The PRGF prepared as described resulted in an increase in platelet concentration. In fact, the count of platelets in peripheral blood ranged from  $142 \times 10^3$  to  $379 \times 10^3$  (mean,  $223 \times 10^3 \pm 71 \times 10^3$  platelets/ $\mu$ L) and from  $421 \times 10^3$  to  $1314 \times 10^3$  (mean,  $634 \times 10^3 \pm 217 \times 10^3$ ) in the PRGF. These data reflect that PRGF had a 3.10-fold (SD, 0.58) increase in the mean platelet concentration. Furthermore, the leukocyte content was also determined in the whole blood and in the PRGF. Results showed that white blood cell content in PRGF was below the detection limit of the coulter, confirming the absence of leukocytes in the PRGF, which improves the homogeneity of the product and reduces donor-to-donor variability. The content of growth factors released from the activated PRGF was also measured for each donor. Mean levels of EGF, VEGF, and HGF were  $481.5 \pm 187.5$  pg/mL,  $383.0 \pm 374.9$  pg/mL, and  $593.87 \pm 155.8$  pg/mL, respectively. On the other hand, mean IGF-I, PDGF, and TGF- $\beta$  concentrations were higher than the above-mentioned factors, reaching  $94.53 \pm 32.84$  ng/mL,  $35.62 \pm 14.57$  ng/mL, and  $74.99 \pm 27.48$  ng/mL, respectively. Another feature of this therapy is the significant positive correlation found between platelet count and the levels of TGF- $\beta$ 1 ( $r = .6157$ ,  $P = .003$ ), PDGF-AB ( $r = .6831$ ,  $P < .001$ ), VEGF ( $r = .5966$ ,  $P = .023$ ), EGF ( $r = .5910$ ,  $P = .029$ ), and HGF ( $r = .6544$ ,  $P = .008$ ). Interestingly, IGF-I showed a significant inverse correlation with age ( $r = -.6897$ ,  $P < .001$ ).

#### DISCUSSION

Surgical repair of the foot and ankle is now advancing toward minimally invasive surgery that tends to allow for a more rapid recovery with less pain. If operative treatment is the right solution, the goal is to minimize complications related to the surgery and promote healing with early functional recovery that does not compromise repair.

In clinical conditions such as Achilles tendon tears, the operative treatment offers a significant reduction in the risk of rerupture and produces better functional results when compared with nonoperative treatment, rendering surgery the most recommended option in athletes.<sup>3,9</sup> However, the number of complications has been estimated as 15% to 20%, rising in parallel with the increasing incidence of ruptures in active people.<sup>3,18,21,26</sup>

Concerns about unpredictable impairment in healing led us to treat tendon tears combining the principles of biology and surgery by applying an autologous platelet-rich fibrin during the operative treatment. The delivery of a complex pool of factors and proteins from the fibrin matrix seeks to better meet the expected need for the repairing tissue.<sup>6</sup>

The idea of using fibrin as a therapeutic tool is not new. Taking advantage of its adhesive properties was proposed years ago as an alternative to suturing in Achilles tendon ruptures.<sup>32</sup> However, clinical results indicated that the procedure was not good enough to be recommended in athletes.<sup>2</sup>

Concepts that have evolved since the development of fibrin glues have given rise to the new platelet-rich technology that overcomes some of the drawbacks associated with fibrin glues. Although fibrin glues provide adhesive properties and scaffolding function, they lack signaling factors. In fact, they are prepared by polymerization of homologous lyophilized fibrinogen through the addition of massive thrombin. In contrast, PRGF provides a bioactive scaffold offering a highly complex pool of signaling factors critical to ensure cell activation and the successful growth of healthy tissue. In previous studies, we showed that tendon cells seeded on autologous PRGF proliferate and synthesize type I collagen, in contrast to fibrin glue. Moreover, tenocytes elicited an angiogenic response by synthesizing VEGF and HGF.<sup>8</sup> Assuming these effects, PRGF treatment would enhance the quality of tendon repair and the time of healing.

We explored the relevance of applying PRGF during open surgery in a group of athletes. The treatment consisted of replacing the natural hematoma, containing a bulk of red blood cells (about 94%) and a little proportion of platelets (6%) and <1% leukocytes, with PRGF, which merely contains platelets embedded in a fibrin matrix.

The fact that tendons are often subjected to high or unusual loads during sports participation reflects better the functional efficacy of this novel procedure. Our study population included 12 carefully matched athletes with total tears of the Achilles tendon. The functional results using this surgical repair and postoperative rehabilitation protocol were within the reported outcomes for this injury.<sup>22,25</sup> Despite the fact that all athletes did well with Achilles repair, the PRGF group required a shorter time in the recovery of motion and return to sporting activities; the latter was a decision that came solely from the sports medicine staff rather than the operating surgeons.

We report 100% healing without any delayed wound healing, sural nerve injury, or superficial or deep infection in the PRGF-treated group. In contrast, minor complications including 1 superficial infection and 2 keloids were described in the control group. Although this study is merely observational, the reported results are in accordance with the proven efficacy of platelet-rich derived therapies in other clinical areas,<sup>4</sup> including the treatment of chronic leg ulcers,<sup>23</sup> articular cartilage surgery,<sup>29</sup> and anterior cruciate ligament reconstruction.<sup>28</sup>

Our study has some inherent weaknesses. It is a retrospective study, and although it represents the first description of tendon treatment with an autologous platelet-rich preparation reported in the literature, the number of patients is small. Further clinical studies are needed to determine the validity of the procedure.

Fully understanding the influence of platelet-rich therapy on healing is an area of developing research. However, advancement in this technology is hindered by the lack of a suitable qualitative and quantitative standardization of the different preparations. Our group has developed an optimized and standardized product known as PRGF that avoids the use of exogenous thrombin. From a safety point of view, PRGF does not contain neutrophils, which express matrix-degrading enzymes, such

as matrix metalloproteinase-8, and release reactive oxygen species that destroy surrounding injured or healthy cells.<sup>6</sup>

Because part of this therapeutic strategy is to increase growth factor concentration at the injured site, we have assessed the most relevant growth factors to tendon healing.<sup>24</sup> Although some of the individual roles of these factors have been described in the scientific literature, their functions could be modified by the presence of other molecules. For example, the presence of TGF- $\beta$ 1 could provide some concerns about application of this therapeutic strategy, as this protein is associated with excessive collagen deposition and scar tissue formation, damaging the mechanical properties of the repaired tissue. We addressed this issue in previous experimental studies and showed that the effect of TGF- $\beta$ 1 on collagen synthesis was counteracted by the presence of other platelet-secreted molecules.<sup>7</sup> Furthermore, when several doses of this plasma were injected weekly in Achilles tendons in sheep, no signs of fibrosis were observed, implying that the use of fibrin matrices may be a safe strategy to initiate and promote healing in damaged tendons.<sup>8</sup> Supporting these findings, our preliminary clinical evidence with PRGF resulted in less increase in width and cross-sectional area in platelet-rich-treated tendons in contrast with the control group, indicating a more physiologic repair with less scar tissue. In addition, it has been reported that platelets also store antibacterial and fungicidal proteins that could prevent infection, although this has yet to be proved.<sup>19</sup>

The method described for the preparation of PRGF is easy to implement and to handle and is applied in a simple way. The risk of disease transmission or an antigenic reaction is nonexistent because autologous blood is not mixed with any other component of animal or human origin.

Based on this preliminary study, we suggest that the operative management of Achilles tendon tears associated with the application of autologous platelet-rich fibrin could present new possibilities for enhanced healing and functional recovery. Although these preliminary results need confirmation in a large cohort of patients, they provide useful information about the safety of this new surgical procedure and open new perspectives in the area of sports medicine, where acceleration of healing is paramount.

## ACKNOWLEDGMENT

The authors are grateful to Dr Yangüela and Dr Orive for their magnetic resonance imaging and ultrasonography expertise. The work of this group is partially funded by the Basque and Spanish governments.

## REFERENCES

1. Abrahamsson SO. Similar effects of recombinant human insulin-like growth factor-I and II on cellular activities in flexor tendons of young rabbits: experimental studies in vitro. *J Orthop Res*. 1997;15:256-262.
2. Ambacher T, Kuhn P, Schmidt R, Disselhorst-Klug C, Paar O. Muscle strength and functional results after surgical repair of Achilles tendon rupture with fibrin gluing. *Zentralbl Chir*. 2001;126:989-994.

3. Amendola N. Surgical treatment of acute rupture of the tendon Achilles led to fewer reruptures and better patient-generated ratings than did nonsurgical treatment. *J Bone Joint Surg Am.* 2002;84:324.
4. Anitua E, Andia I, Ardanza B, Nurden P, Nurden AT. Autologous platelets as a source for healing and tissue regeneration. *Thromb Haemost.* 2004;91:4-15.
5. Anitua E, Andia I, Sanchez M, et al. Autologous preparations rich in growth factors promote proliferation and induce VEGF and HGF production by human tendon cells in culture. *J Orthop Res.* 2005;23:281-286.
6. Anitua E, Sanchez M, Nurden AT, Nurden P, Orive G, Andia I. New insights into and novel applications for platelet-rich therapies. *Trends Biotechnol.* 2006;24:227-234.
7. Anitua E, Sanchez M, Nurden AT, et al. Reciprocal actions of platelet-secreted TGF- $\beta$ 1 on the production of VEGF and HGF by human tendon cells. *Plast Reconstr Surg.* In press.
8. Anitua E, Sanchez M, Nurden AT, et al. Autologous fibrin matrices: a potential source of biological mediators that modulate tendon cell activities. *J Biomed Mater Res A.* 2006;77:285-293.
9. Bhandari M, Guyatt GH, Siddiqui F, et al. Treatment of acute Achilles tendon ruptures: a systematic overview and metaanalysis. *Clin Orthop Relat Res.* 2002;400:190-200.
10. Boyer MI, Watson JT, Lou J, Manske PR, Gelberman RH, Cai SR. Quantitative variation in vascular endothelial growth factor mRNA expression during early flexor tendon healing: an investigation in a canine model. *J Orthop Res.* 2001;19:869-872.
11. Bruggeman NB, Turner NS, Dahm DL, et al. Wound complications after open Achilles tendon repair. *Clin Orthop Relat Res.* 2004;427:63-66.
12. Carter CA, Jolly DG, Worden CE, Hendren DG, Kane CJM. Platelet-rich plasma gel promotes differentiation and regeneration during equine wound healing. *Exp Mol Pathol.* 2003;74:244-255.
13. Chan BP, Fu SC, Qin L, Lee KM, Rolf CG, Chan KM. Effects of basic fibroblast growth factor (bFGF) on early stages of tendon healing: a rat patellar tendon model. *Acta Orthop Scand.* 2000;71:513-518.
14. Dahlgren LA, Mohammed HO, Nixon AJ. Temporal expression of growth factors and matrix molecules in healing tendon lesions. *J Orthop Res.* 2005;23:84-92.
15. Hsu CH, Chang J. Clinical implications of growth factors in flexor tendon wound healing. *J Hand Surg [Am].* 2004;29:551-563.
16. Kannus P, Józsa L, Järvinen M. Epidemiology and histology of Achilles tendon rupture. *Foot Ankle Clin.* 1997;2:475-500.
17. Kannus P, Natri A. Etiology and pathophysiology of tendon ruptures in sports. *Scand J Med Sci Sports.* 1997;7:107-112.
18. Khan RJ, Fick D, Brammar TJ, Crawford J, Parker MJ. Interventions for treating Achilles tendon ruptures. *The Cochrane Library.* 2005;2:1-54.
19. Krijgsveld J, Zaat SA, Meeldijk J, et al. Thrombocidins, microbicidal proteins from human blood platelets, are C-terminal deletion products of CXC chemokines. *J Biol Chem.* 2000;265:20374-20381.
20. Kurtz CA, Loebig TG, Anderson DD, Demeo PJ, Campbell PG. Insulin-like growth factor I accelerates functional recovery from Achilles tendon injury in a rat model. *Am J Sports Med.* 1999;27:363-369.
21. Leppilahti J, Forsman K, Puranen J, Orava S. Outcome and prognostic factors of Achilles rupture repair using a new scoring method. *Clin Orthop Relat Res.* 1998;364:152-161.
22. Maffulli N, Tallon C, Wong J, Peng Lim K, Bleakney R. No adverse effect of early weight bearing following open repair of acute tears of the Achilles tendon. *J Sports Med Phys Fitness.* 2003;43:367-379.
23. Margolis DJ, Kantor J, Santana J, Strom BL, Berlin JA. Effectiveness of platelet releasate for the treatment of diabetic neuropathic foot ulcers. *Diab Care.* 2001;24:483-488.
24. Molloy T, Wang Y, Murrell GAC. The roles of growth factors in tendon and ligament healing. *Sports Med.* 2003;33:381-394.
25. Mortensen NHM, Skov O, Jensen PE. Early motion of the ankle after operative treatment of a rupture of the Achilles tendon: a prospective, randomized clinical and radiographic study. *J Bone Joint Surg Am.* 1999;81:983-990.
26. Pajala A, Kangas J, Ohtonen P, Leppilahti J. Rerupture and deep infection following treatment of total Achilles tendon rupture. *J Bone Joint Surg Am.* 2002;84:2016-2021.
27. Rickert M, Jung M, Adiyaman M, Richter W, Simank HG. A growth and differentiation factor-5 (GDF-5)-coated suture stimulates tendon healing in an Achilles tendon model in rats. *Growth Factors.* 2001;19:115-126.
28. Sánchez M, Azofra J, Aizpurúa B, Elorriaga R, Anitua E, Andia I. Use of autologous plasma rich in growth factors in arthroscopic surgery [in Spanish]. *Cuadernos de Artroscopia.* 2003;10:12-19.
29. Sánchez M, Azofra J, Anitua E, et al. Plasma rich in growth factors to treat an articular cartilage avulsion: a case report. *Med Sci Sports Exerc.* 2003;35:1648-1652.
30. Smith FW, Roselund EA, Aune AK, MacLean JA, Hillis SW. Subjective functional assessments and the return to competitive sport after anterior cruciate ligament reconstruction. *Br J Sports Med.* 2004;38:279-284.
31. Wapner KL. Acute repair of the Achilles tendon. In: Johnson KA, ed. *The Foot and Ankle.* New York, NY: Raven Press; 1991:299-309.
32. Winter U. Treatment of fresh Achilles tendon ruptures with fibrin glue. *Aktuelle Traumatol.* 1985;15:219-221.
33. Ying M, Yeung E, Li B, Li W, Lui M, Tsoi CW. Sonographic evaluation of the size of Achilles tendon: the effect of exercise and dominance of the ankle. *Ultrasound Med Biol.* 2003;29:637-642.
34. Yoshikawa Y, Abrahamsson O. Dose-related cellular effects of platelet-derived growth factor-BB differ in various types of rabbit tendons in vitro. *Acta Orthop Scand.* 2001;72:287-292.