
Chronic Medial Collateral High-Grade Tear: Treatment with autologous platelet concentrate injection with ultrasound guidance: A Case Report

Dr. Michael A. Scarpone, D.O.

Clinical History:

69 YO male with severe leg pain and knee pain with 'giving out' with walking and ADL's. Patient was hit by a car at a drag race. The injury occurred September 6. He had Physical Therapy for 5 weeks and bracing.

Patient Symptoms & Signs:

- Knee Pain
- Knee Buckling & giving out
- Laxity of MCL on Valgus stressing the knee at 30° of flexion

MRI Diagnosis - 7/15/07 (fig.1):

Severe sprain of the medial collateral ligament with partial high-grade rupture of the superficial fibers proximally at the medial insertion to the medial femoral condyle.

Description of Procedure - 7/26/07:

- Using aseptic technique and US guidance with local anesthesia a 22-gauge 3" needle was passed from the distal to the proximal segments of the torn MCL.
- APC was then implanted with thrombin/calcium chloride from the proximal MCL segment through the gap into the distal MCL fragment.
- A sterile pressure dressing was applied.

Patient Follow-up:

8/17/07: Some reduction in pain. Knee buckling is improved, but still present. Stiffness in leg all day and cannot squat well. Patient scheduled for second PRP procedure.

Description of Second PRP Procedure - 8/23/07:

Same as first procedure.

Patient Follow-up:

9/20/07: No pain, no more knee buckling, stiffness only last about 5-10 minutes after waking up, and can squat 90%. Fully functional, no limitations. No MCL laxity on exam.

10/31/07: No pain no knee buckling, only slight stiffness with squatting. Fully functional, no limitations. No MCL laxity with Valgus stress testing.

Post MRI – 10/31/07 (fig.2):

Normal fibular collateral ligaments and biceps femoris tendon complex. Normal iliotibial band. There is no evidence of injury to the post-lateral corner, including the popliteus myotendinous complex.

There is thickening of the superficial fibers of the medial collateral ligament, without surrounding edema, consistent with interval healing. No acute ligamentous tear is noted.

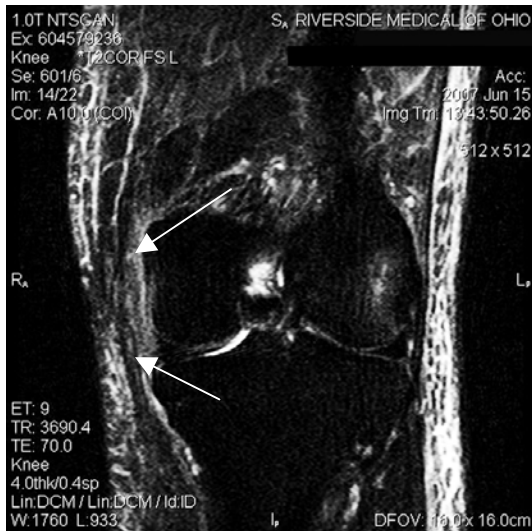

Fig.1 (7/15/07)
High-grade MCL Tear

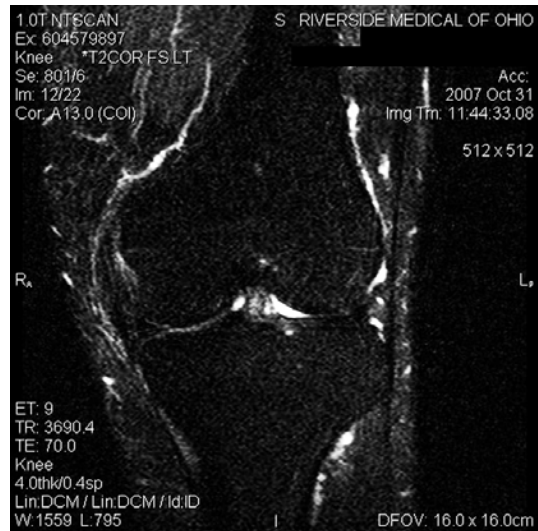
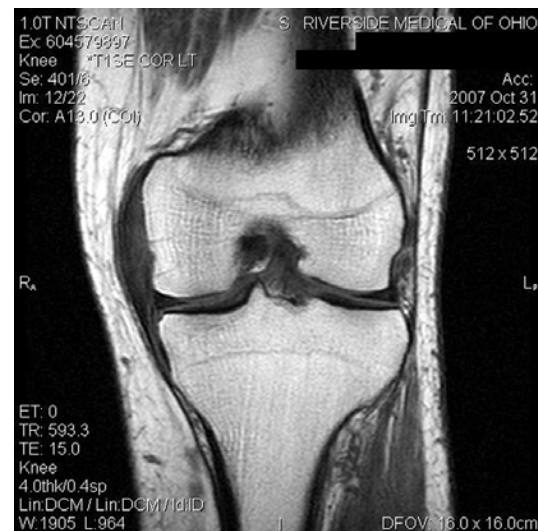
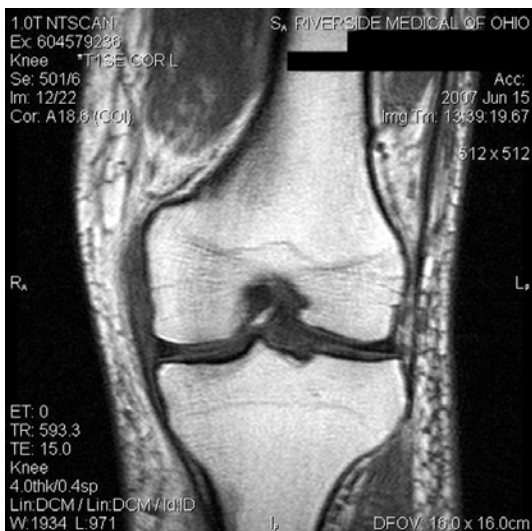
Fig.2 (10/31/07)
Healing MCL



Conclusion:

Autologous platelet grafting can be an effective minimally invasive treatment on chronic MCL sprains refractory to conservative treatment. The Harvest SmartPReP process for concentrating autologous platelet rich plasma is a fairly simple outpatient procedure.